第46回岡山大学脳神経外科同門会/岡山ﾌﾟﾗｻﾞﾎﾃﾙ/20121124

第1回岡山大学医学部脑神経外科同門会賞受賞記念講演

Trigeminal Neuralgia: Diagnosis Using 3-D Magnetic Resonance Multi-Fusion Imaging

Tumors of the Central Nervous System
Volume 4. Brain Tumors (Part 2)
pp 199-209, Hayat MA Ed, Chapter 20,
Springer, New York, 2012

佐藤　透 (Toru Satoh)
小野田　恵介 (Keisuke Onoda)
伊達　勲 (Isao Date)

医療法人社団) 涼風会 佐藤脑神経外科

佐藤 透

第1回岡山大学医学部脳神経外科同門会賞受賞記念講演

AJNR Am J Neuroradiol 26: 2010–2018, September 2005



AJNR Am J Neuroradiol 26:2010–2018, September 2005

Influence of Perianeurysmal Environment on the Deformation and Bleb Formation of the Unruptured Cerebral Aneurysm: Assessment with Fusion Imaging of 3D MR Cisternography and 3D MR Angiography

Toru Satoh, Megumi Omi, Chika Ohsako, Atsushi Katsumata, Yusuke Yoshimoto, Shoji Tsuchimoto, Keisuke Onoda, Koji Tokunaga, Kenji Sugiu, and Isao Date

BACKGROUND AND PURPOSE: **Surface irregularity and bleb formation are anatomical factors that are associated with aneurysm rupture. The perianeurysmal environment has been proposed as one factor that may influence aneurysm morphology. We have developed a fusion**
nd angiography that allows clear visualization of
que may prove useful in further understanding
ns.
ography and angiography were reconstructed by
m the volume datasets of MR cisternography,
equence, and coordinated MR angiography, by a
es, the anatomic relationship of an aneurysm to
nd the influence of perianeurysmal environment
aneurysm was investigated.
nd bleb formation of the aneurysmal dome were
certain contact with perianeurysmal structures,
anial base bones, petroclinoidal dural folds, and

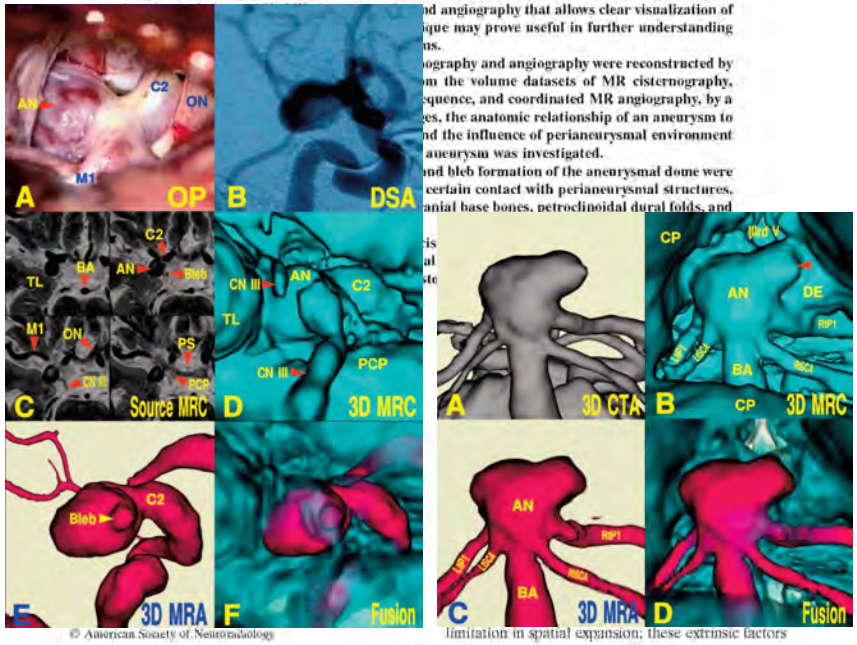

© American Society of Neuroradiology

limitation in spatial expansion; these extrinsic factors

Toru SATOH S-3

送信者： "Toru SATOH G2" <ucsfstrc@urban.ne.jp>
宛先： "a透urban" <ucsfstrc@urban.ne.jp>
送信日時： 2012年6月20日 15:12
件名： 20100514-Invitation to Contribute

----- Original Message -----
From: Eric Hayat
To: ucsfstrc@urban.ne.jp
Sent: Friday, May 14, 2010 12:14 AM
Subject: [***Spam***](Default) Invitation to Contribute

Dr. Toru Satoh
Department of Neurosurgical Surgery,
Ryofukai Satoh Neurosurgical Hospital,
5-23-23 Matsunaga, Fukuyama, Hiroshima,
729-0101, Japan

Dear Dr.Satoh:

Springer Company is planning to publish a five-volume series in the field of TUMORS OF THE CENTRAL NERVOUS SYSTEM, which will be edited by me. The emphasis in this series is also on the diagnosis, therapy, and prognosis of the disease. An international team of leading experts in the field representing 19 countries are participating in this important new project. This series is being published for world-wide distribution. A partial list of contributors and their topics is attached. If you wish, you can invite a coauthor(s) to join you.

It is my hope that you will join us to complete this project. Your participation will be an asset to this endeavor. The main author will be offered a copy gratis of the volume. The main author will also be offered an appropriate honorarium (decided by the publisher) after a sufficient number of books have been sold. If you are able to join us, please let me know at your earliest convenience through e-mail or telephone. I would also appreciate having your fax, and telephone number. To assist you in preparing the manuscript in terms of the format, a copy of a sample manuscript is attached. Please follow strictly this format to avoid retyping. If you have any questions, please do not hesitate to contact me. The subject of your chapter is indicated below; please let me know if you wish to suggest a change in topic. Please start your manuscript with an abstract, followed by an introduction. The deadline is the end of August, 2010.

TRIGEMINAL NEURALGIA: DIAGNOSIS USING MAGNETIC RESONANCE IMAGING

Sincerely,

Dr. M. A. Hayat
Distinguished professor
Biology Department
Kean University
Union, NJ 07083, USA
E-mail: ehayat@kean.edu

第1回岡山大学医学部脳神経外科同門会賞受賞記念講演

Tumors of the Central Nervous System, Volume 4. Brain Tumors (Part 2), pp 199–209, Hayat MA Ed, Chapter 20, Springer, New York, 2012

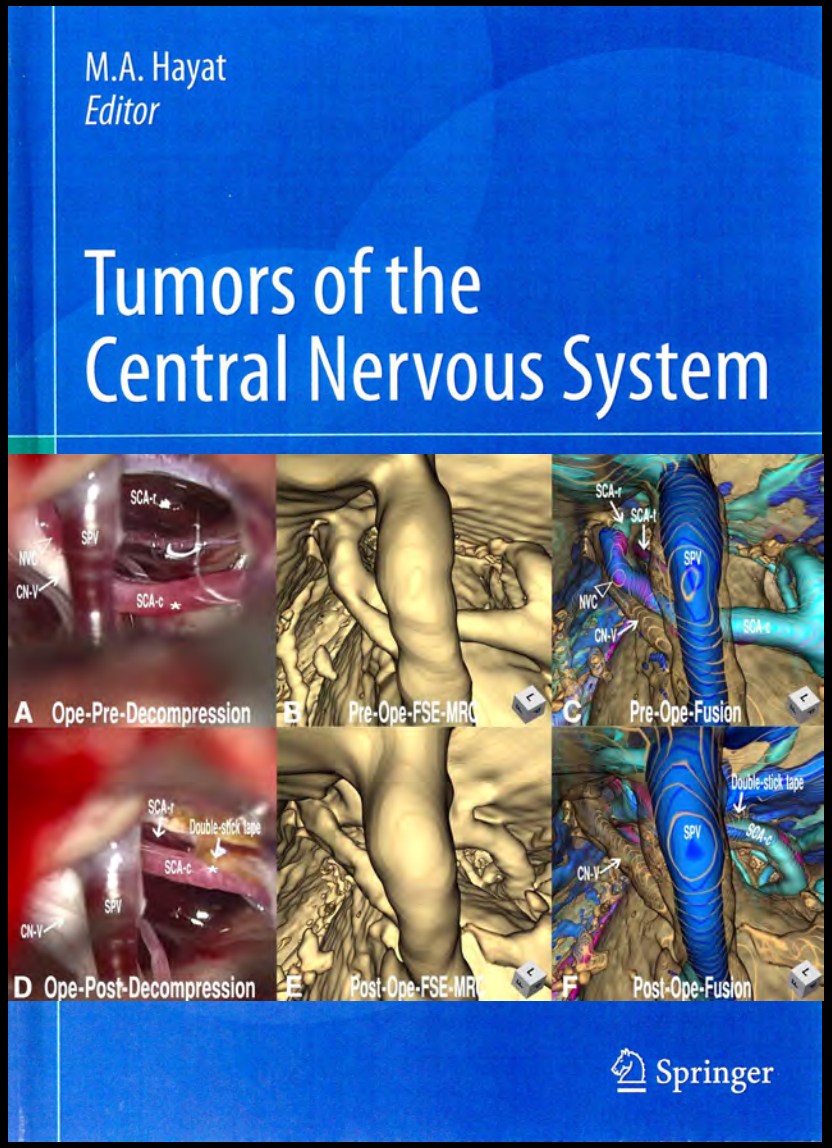

Chapter 20

Trigeminal Neuralgia: Diagnosis Using 3-D Magnetic Resonance Multi-Fusion Imaging

Toru Satoh, Keisuke Onoda, and Isao Date

Abstract Most instances of idiopathic trigeminal neuralgia (TN) are caused by neurovascular contact (NVC) between the offending vessels and the affected trigeminal nerve. Pre-treatment analysis of the MR imaging findings on the severity of the NVC may predict the outcomes of microvascular decompression (MVD) surgery or radiosurgical treatment. In order be useful for adjunctive diagnosis, planning of the best treatment strategy, and post-treatment follow-up in patients with TN.

Keywords Trigeminal neuralgia · Neurovascular compression syndrome · Cranial nerves · Meckel cave · MVD · NVC

A Operative-View
B Pre-Ope-Fusion-1
C Pre-Ope-Fusion-2
D Pre-Post-Ope-Fusion-1
E Pre-Post-Ope-Fusion-2
F Post-Ope-CTA

Neurosurgical Hospital, 5-23-23 Matsunaga, Fukuyama, Hiroshima 729-0104, Japan
e-mail: uesfbtrc@urban.ne.jp

ric data regarding the anatomic elements composing the NVC, including the trigeminal nerve and artery or vein, with surrounding brain parenchyma, dura

M.A. Hayat (ed.), *Tumors of the Central Nervous System, Volume 4*,
DOI 10.1007/978-94-007-1706-0_20, © Springer Science+Business Media B.V. 2012

199

第1回岡山大学医学部脳神経外科同門会賞受賞記念講演

脳神経外科速報　21(1): 175-183, 2011, 21(2): 186-195, 2011

脳神経外科速報 vol.21 no.1 000—000, 2011

Current Topic

今月のテーマ 画像評価

3-D multi-fusion imagingによる神経血管圧迫症候群の画像評価 ～基礎編：画像再構成作成技術～

佐藤　透[1] 小野田恵介[2] 伊達　勲[3]
Toru SATOH[1], Keisuke ONODA[2], Isao DATE[3]

1) 医療法人社団波風会佐藤脳神経外科　〒729-0104　広島県福山市松永町 5-23-23
2) 総合病院岡山赤十字病院脳神経外科
3) 岡山大学大学院脳神経外科

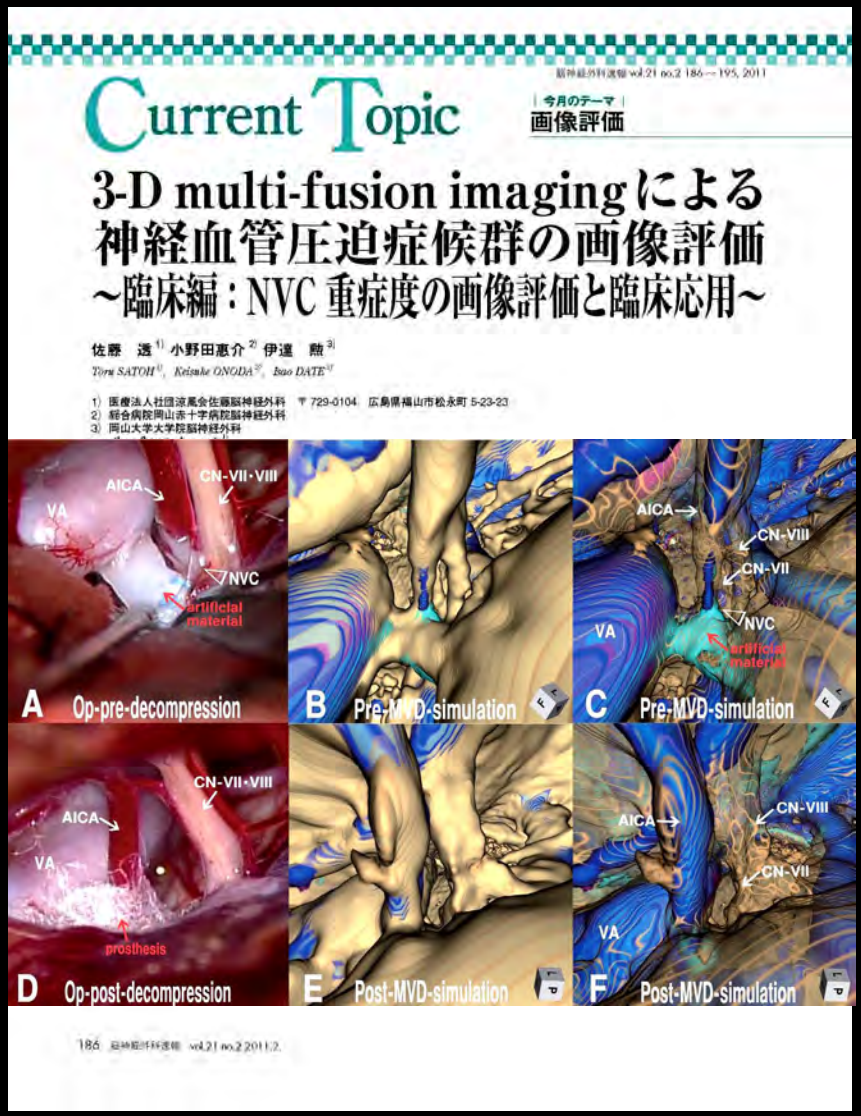

脳神経外科速報 vol.21 no.2 186—195, 2011

Current Topic

今月のテーマ 画像評価

3-D multi-fusion imagingによる神経血管圧迫症候群の画像評価 ～臨床編：NVC 重症度の画像評価と臨床応用～

佐藤　透[1] 小野田恵介[2] 伊達　勲[3]
Toru SATOH[1], Keisuke ONODA[2], Isao DATE[3]

1) 医療法人社団波風会佐藤脳神経外科　〒729-0104　広島県福山市松永町 5-23-23
2) 総合病院岡山赤十字病院脳神経外科
3) 岡山大学大学院脳神経外科

第1回岡山大学医学部脳神経外科同門会賞受賞記念講演

J Neurosurg 106: 82–89, Jan 2007

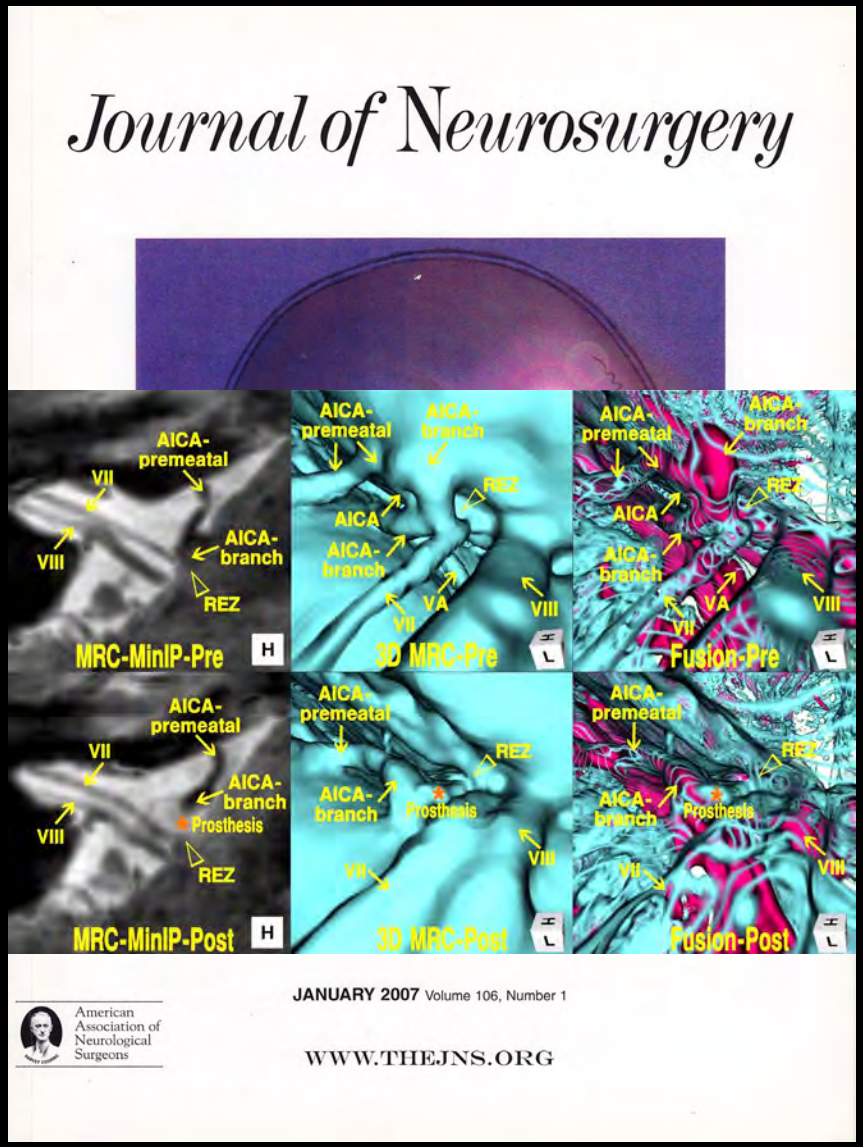

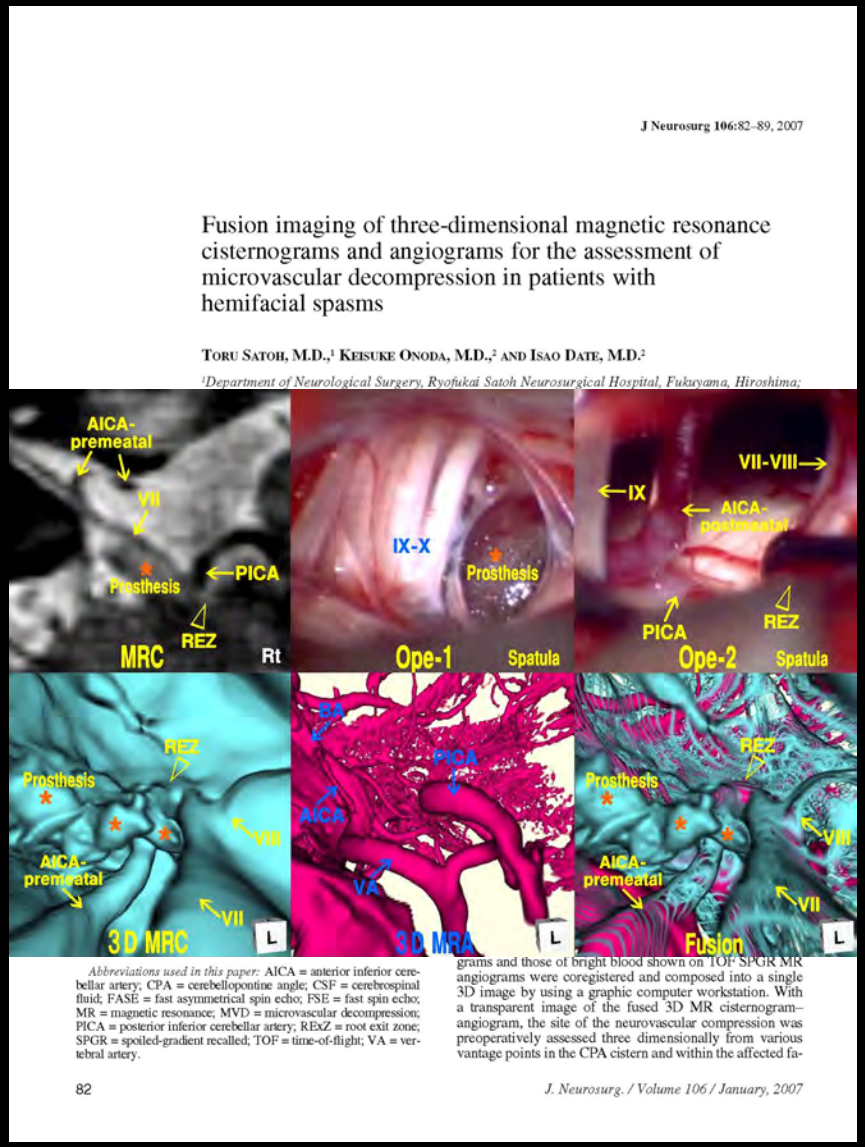

第1回岡山大学医学部脳神経外科同門会賞受賞記念講演

Neurosurgery 60: 104–114, Jan 2007

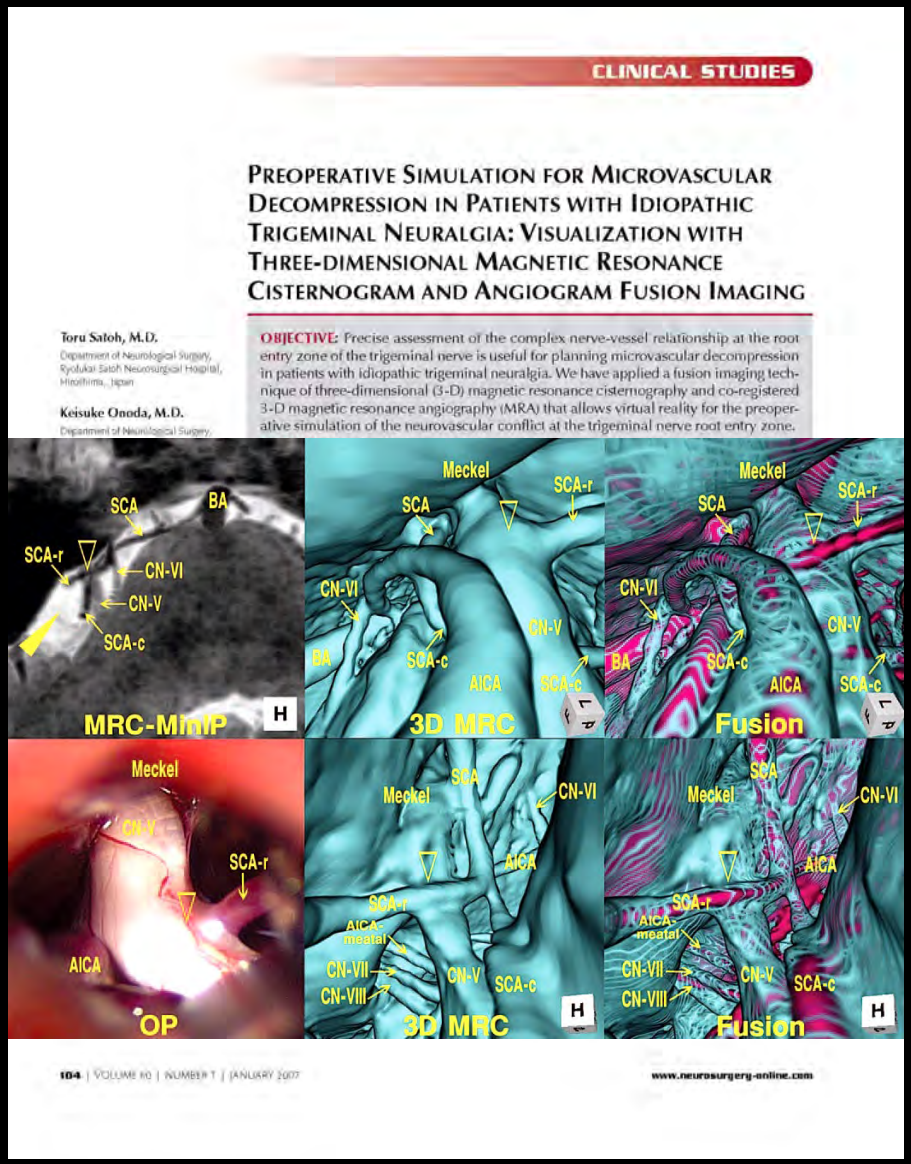

CLINICAL STUDIES

PREOPERATIVE SIMULATION FOR MICROVASCULAR DECOMPRESSION IN PATIENTS WITH IDIOPATHIC TRIGEMINAL NEURALGIA: VISUALIZATION WITH THREE-DIMENSIONAL MAGNETIC RESONANCE CISTERNOGRAM AND ANGIOGRAM FUSION IMAGING

Toru Satoh, M.D.
Department of Neurological Surgery, Ryokuka Satoh Neurosurgical Hospital, Hiroshima, Japan

Keisuke Onoda, M.D.
Department of Neurological Surgery,

OBJECTIVE: Precise assessment of the complex nerve-vessel relationship at the root entry zone of the trigeminal nerve is useful for planning microvascular decompression in patients with idiopathic trigeminal neuralgia. We have applied a fusion imaging technique of three-dimensional (3-D) magnetic resonance cisternography and co-registered 3-D magnetic resonance angiography (MRA) that allows virtual reality for the preoperative simulation of the neurovascular conflict at the trigeminal nerve root entry zone.

104 | VOLUME 60 | NUMBER 1 | JANUARY 2007 www.neurosurgery-online.com

第1回岡山大学医学部脳神経外科同門会賞受賞記念講演

AJNR Am J Neuroradiol 30: 603–607, Mar 2009

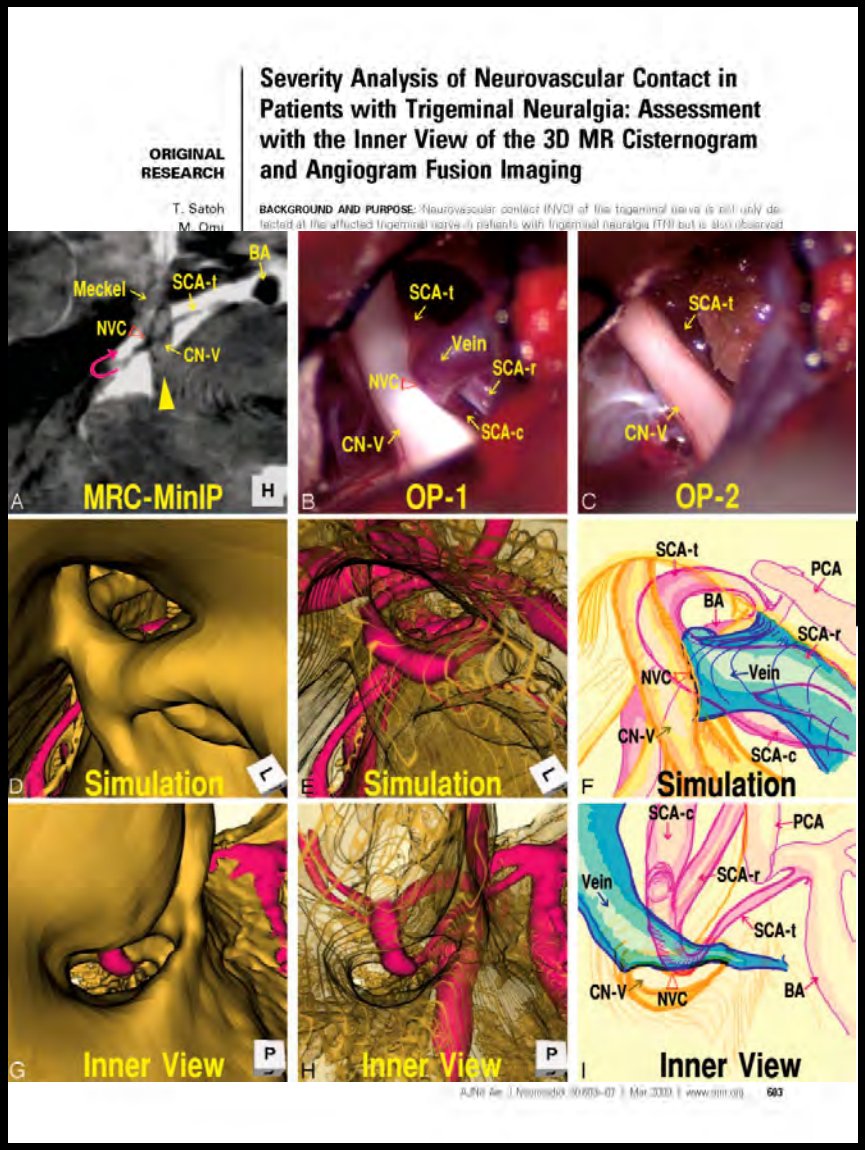

第1回岡山大学医学部脳神経外科同門会賞受賞記念講演

Seeing is Believing:　百聞は一見にしかず

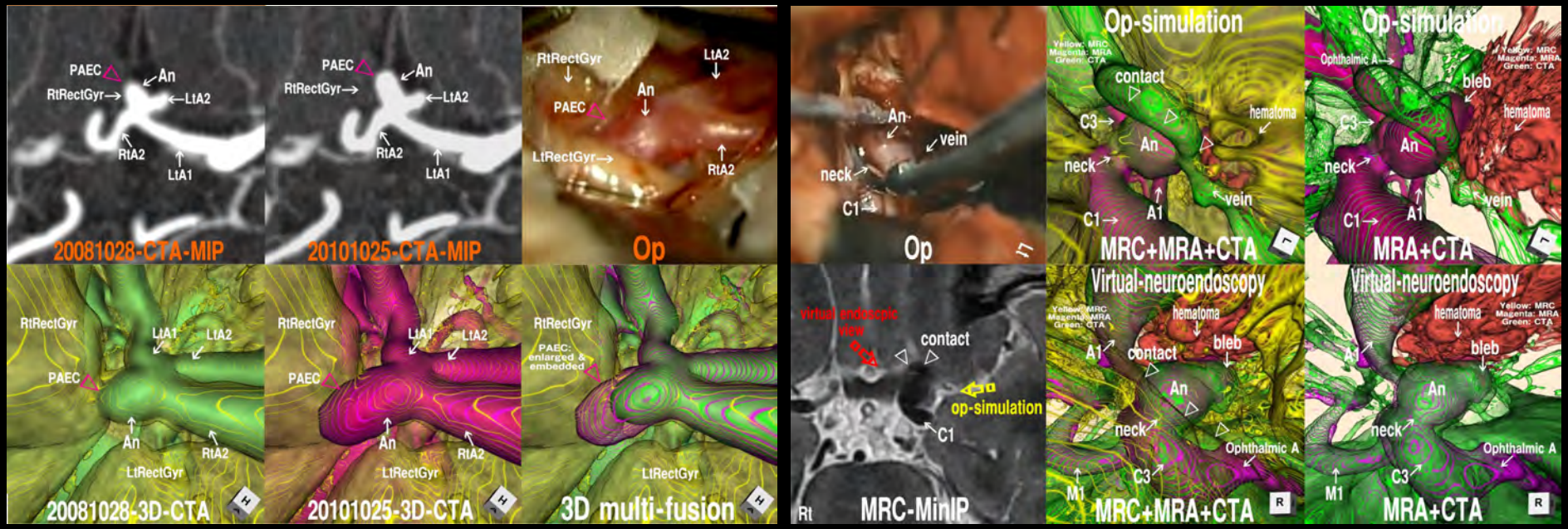

第46回岡山大学脳神経外科同門会/岡山ﾌﾟﾗｻﾞﾎﾃﾙ/20121124

本日は、栄誉ある同門会賞をいただき、有難うございました

医療法人社団）涼風会 佐藤脳神経外科 佐藤 透